



DATE PRESENTING CLINICAL SIGNS

1.13.26

History: Weight loss. Elevated BNP.
-Current medications: None listed.
-Sedation used: Not required to complete full diagnostic ultrasound.

PATIENT

Tobin Sandless

-Pertinent previous ultrasound results:
-STAT: Not requested.
-Imaging performed by: Andi Parkinson, BS, RDMS.

SPECIES ECHOCARDIOGRAM FINDINGS

Canine

2D, m-mode, color flow and doppler imaging is available. Mild thickening of the mitral valve leaflets with no prolapse into the left atrial lumen. No mitral regurgitation with no left atrial dilation. Normal LV diameter with adequate myocardial function. The tricuspid valve appears normal with no significant tricuspid regurgitation. Normal right atrial and ventricular diameter and morphology indicating no overt evidence of pulmonary arterial hypertension. The pulmonic and aortic valves are normal in morphology and mobility. Normal pulmonic and aortic outflow velocities with laminar flow. No obvious aortic and trace pulmonic insufficiency. No pericardial or pleural effusion noted. No obvious cardiac masses.

BREED

Lab

SEX

MN

CARDIAC CHART

AGE

9.1.15

WEIGHT

109lbs

INTERPRETED BY

Maggie Machen Lamy,
DVM, DACVIM
(Cardiology)

HOSPITAL NAME

Homeward Bound VS

REFERRING VET

Dr. Vance

CANINE CARDIAC PARAMETERS	MR VMAX (m/s)	TR VMAX (m/s)	LA/AO (Boon method)	LA/AO (Heart Base; Swe)	FS (%)	EF (%)	EPSS (cm)
NORMAL PARAMETER	4.5-5.5	<2.7	1.3	<1.6	28-40	40-100	<0.6
PATIENT	NA	NA	NM	1.2	32	60	NM
CANINE CARDIAC PARAMETERS	HR (BPM)	AV VMAX (m/s)	PV MAX (m/s)	BODY WEIGHT (kg)	LA 2D short axis Base view (cm)	LVIDd Avg; 2D and m-mode short axis (cm)	LVIDs Avg; 2D and m-mode short axis (cm)
NORMAL PARAMETER	50-100	0.7-1.7	0.7-1.6	BELOW	BELOW	BELOW	BELOW
PATIENT	140	1.4	0.7	49.4	2.8	4.5	3.4
*Normal chamber parameters expressed as a mean value (SD)				3	1.27 (5.3)	2.46 (2.46)	1.36 (5.5)
BODY WEIGHT DEPENDENT PARAMETERS				5	1.40 (4.5)	2.74 (5.2)	1.60 (4.7)
*Note: All measurements based upon multi-modal images and methods. An average value is reported.				10	1.50 (3.8)	3.27 (3.5)	2.06 (3.1)
				15	1.83 (2.0)	3.71 (2.4)	2.43 (2.1)
				20	2.02 (1.9)	4.14 (2.2)	2.80 (2.0)
				25	2.18 (2.4)	4.48 (2.9)	3.10 (2.5)
				30	2.33 (3.3)	4.83 (3.9)	3.39 (3.4)
				35	2.48 (4.3)	5.17 (5.0)	3.69 (4.5)
				40	2.62 (5.2)	5.48 (6.1)	3.96 (5.4)
				50	2.88 (7.1)	6.07 (8.3)	4.46 (7.4)

Adapted from June Boon, Veterinary Echocardiography, 1998
Rishniw M and Hollis NE, J Vet Intern Med 2000; 14:429-435
Hansson et al, Vet Rad and Ultrasound 2002
Bonagura et al. Echocardiography: principles of interpretation, Vet Clin North Am 15:1177, 1995

INVOICE INTERPRETATION OF THE FINDINGS & FURTHER RECOMMENDATIONS

46425

The cardiac structure and function in this patient is overtly normal. No significant valvular regurgitation is noted, and flow through the great vessels is normal. No obvious concurrent issues such as pulmonary hypertension are suspected.

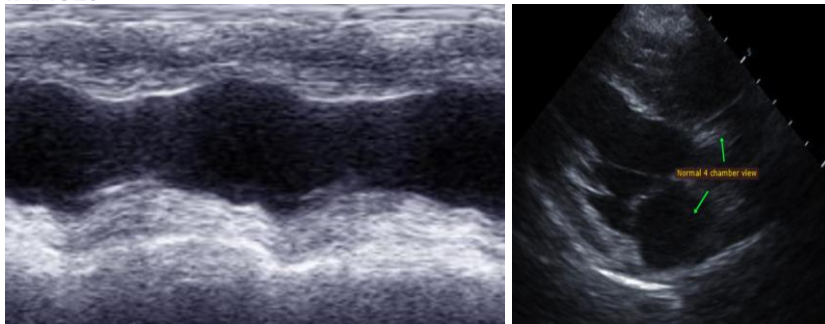
A structural cause for NT-ProBNP elevation is not apparent here, making this potentially a false positive result (a known weakness of the test particularly in this breed). Other possible causes for elevated levels of the enzyme should be considered, such as significant arrhythmias, hyperthyroidism, systemic hypertension or renal disease. If no obvious cause is identified, reassessing this patient in 6-12 months is recommended to ensure early disease was not missed.

No cardiac medications are indicated at this time and the prognosis is open. Monitor for development of a cough, labored breathing, exercise intolerance or collapse episodes.

No cardiac contraindication for general anesthesia.

A recheck is recommended in 6-12 months to ensure no progressive issues are identified, sooner should a murmur or any clinical signs of cardiac compromise be noted in the interim.

IMAGES



The information and recommendations provided are based on the images presented by the referring veterinarian. No evaluation can be communicated regarding pathology that was not visible in the image/video clips provided.

Thank you for this referral. This report was generated using transcription software, and minor dictation errors may be present. If the clinical or image interpretation does not parallel your findings or if I can be of any further assistance, please contact me.

Maggie Machen Lamy, DVM
Diplomate of the American College of Veterinary Internal Medicine (Cardiology)
info@sonopath.com